RA hand		RA knee	OA knee
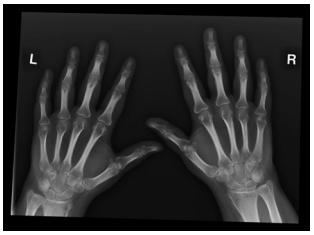			

Which of the following is NOT a characteristic radiographic finding in rheumatoid arthritis (RA)?

A. Erosion of the ulnar styloid
B. Marginal bony erosions
C. Asymmetric joint involvement
D. Uniform joint space narrowing

In patients with **RA**, characteristic changes on x-ray are as follows:	
• uniform joint space narrowing • symmetric joint involvement • marginal bony erosions • juxta-articular osteopenia • radial deviation of the radiocarpal joint (carpal and metacarpals)	• ulnar deviation of phalanges • erosion of the ulnar styloid • atlantoaxial subluxation • small joint involvement, including MCP, PIP, carpal joints

What is the "gold standard" for diagnostic imaging in rheumatoid arthritis (RA)?

A. Ultrasound
B. Magnetic resonance imaging (MRI)
C. Bone scan
D. Plain radiograph

- Plain radiograph remains the "gold standard" for diagnostic imaging in rheumatoid arthritis.

Swan-neck deformity	Boutonniere deformity
DIP flexion + PIP hyperextension	DIP hyperextension + PIP flexion
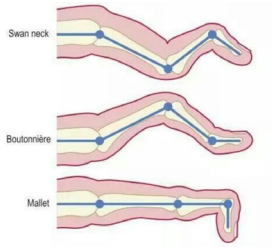	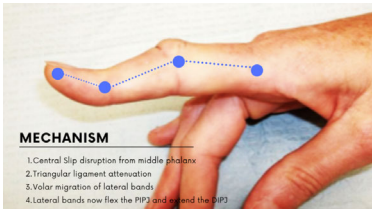

What is the position of a swan-neck deformity of the finger typical in rheumatoid arthritis?

A. Hyperextension of the proximal interphalangeal joint (PIP) with hyperextension of the distal interphalangeal joint (DIP)
B. Hyperextension of the PIP with flexion of the DIP
C. Flexion of the PIP with flexion of the DIP
D. Flexion of the PIP with hyperextension of the DIP

- A Swan-neck deformity can be seen in the hands of **RA** patients and is hyperextension of the PIP with flexion of the DIP. There is also flexion at the metacarpophalangeal joint (MCP).
- It is caused by chronic inflammation at the PIP, which causes a stretch of the volar plate. The PIP joint then moves into hyperextension. At the DIP, there is elongation or rupture of the extensor hood at the base of the phalanx.

	MCP	PIP	DIP
Swan-neck deformity	∧	∨	∧
Boutonniere deformity	∨	∧	∨

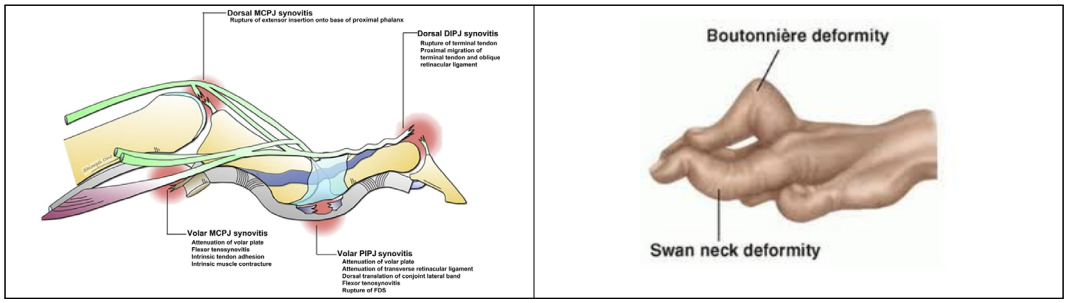

Which of the following finger deformities common in patients with rheumatoid arthritis is caused by synovitis of the metacarpophalangeal (MCP) or distal interphalangeal (DIP) joints creating a flexion contracture of the MCP joint, hyperextension of the PIP joint, and flexion of the DIP joint?

A. Swan neck deformity
B. Boutonniere deformity
C. Ulnar deviation
D. Flexer tenosynovitis

- In contrast to a Boutonniere deformity, a **Swan neck deformity** is caused by synovitis of the metacarpophalangeal (MCP) or distal interphalangeal (DIP) joints creating a flexion contracture of the MCP joint, hyperextension of the PIP joint, and flexion of the DIP joint.
- Ulnar deviation of the fingers in patients with rheumatoid arthritis is secondary to unrestrained pull of the ulnar finger flexors.
- Flexor tenosynovitis commonly affects the extensor pollicis brevis (EPB) and abductor pollicis longus (APL) tendons (ie, DeQuervain's tenosynovitis) causing radial-sided wrist pain.

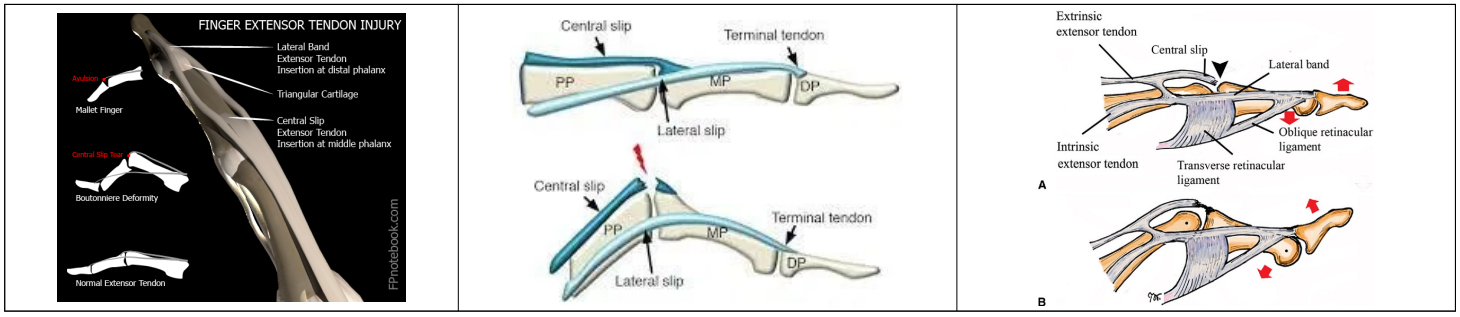

Which of the following finger deformities common in patients with rheumatoid arthritis is characterized by rupture of the terminal portion of the extensor hood and subluxation of the lateral bands?

A. Swan neck deformity
B. Flexor tenosynovitis
C. Boutonniere deformity
D. Ulnar deviation

What causes a Boutonnière deformity?

A. Rupture of the central slip at the PIP, which causes subluxation of the lateral bands of the extensor hood
B. Flexor synovitis
C. Ligamentous laxity
D. Rupture of the flexors with subluxation causing hyperextension at the PIP

- **Boutonnière deformity** is characterized by weakness or rupture of the terminal portion of the extensor hood, which holds the lateral bands in place at the PIP joint.
- There is initially PIP synovitis then a downward slippage of the lateral bands, causing flexion at the PIP joint.

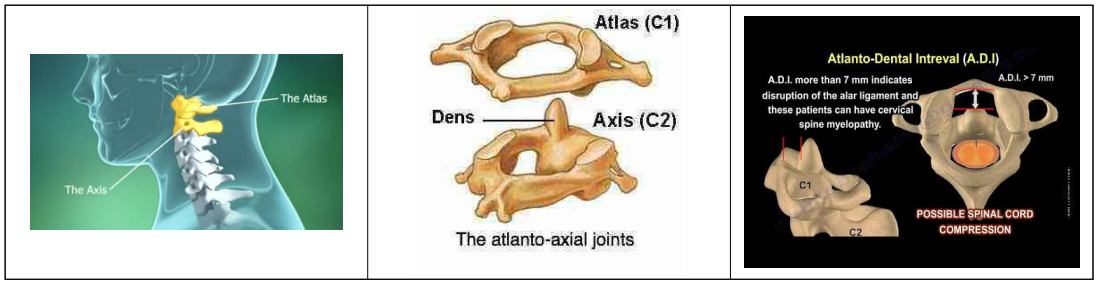

A 42-year-old female with a history of rheumatoid arthritis (RA) presents to the office with complaints of chronic neck pain. Which of the following radiological findings should prompt referral to a spine surgeon?

A. Stability of the atlantoaxial (AA) articulation on lateral flexion/extension radiographs
B. Disc space narrowing with associated endplate sclerosis on lateral radiographs
C. Schmorl's nodes noted on sagittal MRI scan
D. Erosion of the odontoid on sagittal MRI scan

- Erosion of the odontoid and AA instability is a classic presentation of **RA** affecting the cervical spine. A distance greater than 2.5 mm between the inferior aspect of the posterior arch of C1 and the anterior dens is diagnostic of instability typically from disruption of the transverse ligament by pannus formation. Axial migration of C2 is not uncommon as the odontoid erodes and a potential space is created.
- Any of these radiological findings in a patient with **RA** (even in the presence of a normal neurological examination) should prompt referral to a spine surgeon for consideration of an occipital-cervical fusion as these patients are at heightened risk for sudden death secondary to brainstem or spinal cord compression.
- Disc space narrowing with associated sclerosis and Schmorl's nodes (intravertebral disc herniations) in the absence of any of the other radiological findings would not necessitate surgical spinal consultation.

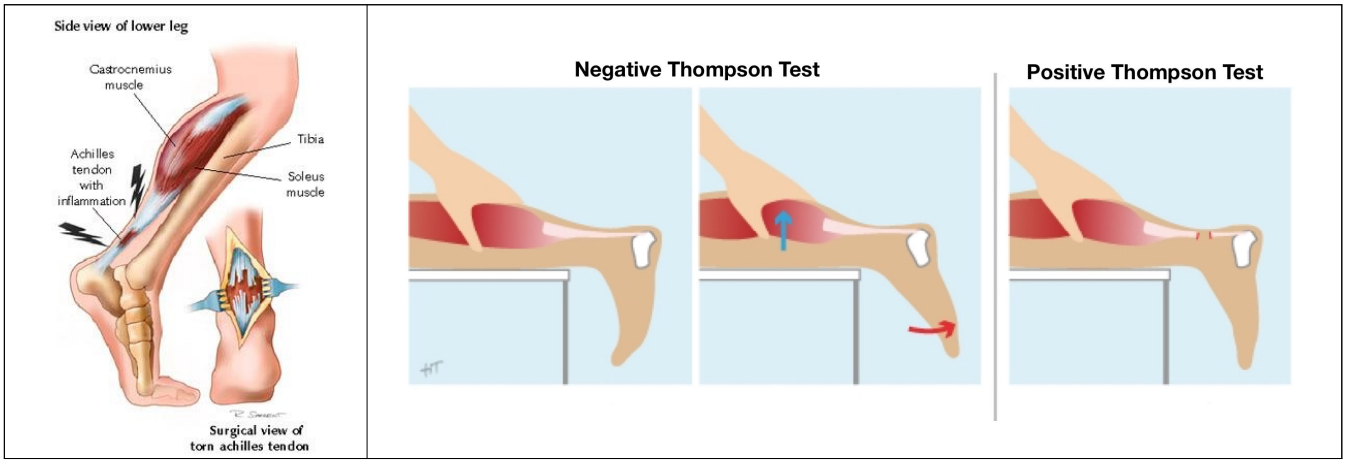

A 66-year-old woman with a history of rheumatoid arthritis (RA) presents with a 3-week history of right ankle and calf pain with difficulty walking. She reports that her RA affects her hands, wrists, and ankles the most. Two weeks ago, she fell while walking at home and has been using a manual wheelchair since then. On exam, both ankles have a mild effusion and her right calf is tender to palpation. She has a positive Thompson test on the right, but not on the left. What test/procedure would be most diagnostic?

A. Joint aspiration
B. Magnetic resonance imaging
C. Plain radiograph
D. Venous ultrasound

- The patient has a right Achilles tendon tear likely secondary to tenosynovitis from her **RA**. Most tendon ruptures in RA are abrupt. Her examination is characteristic of an acute Achilles tendon rupture with lack of plantar flexion on calf squeeze (ie, a positive Thompson test). An MRI scan of the right ankle will most readily demonstrate interstitial tearing of the tendon.
- Joint aspiration, plain radiograph, and venous ultrasound would not be diagnostic.

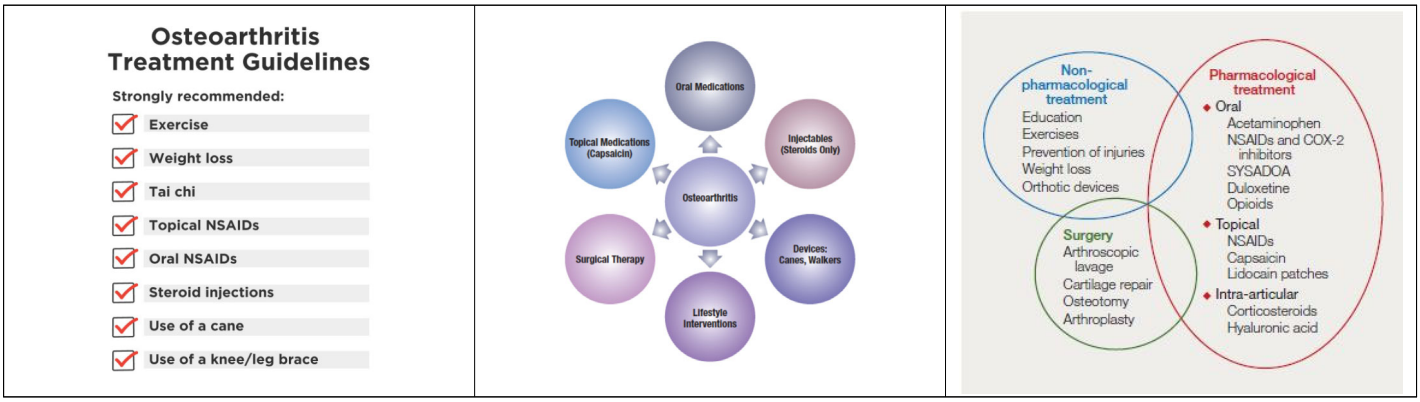

Which management strategy for knee osteoarthritis is associated with the longest-term reduction in pain symptoms and improvement in function?

A. Weight loss
B. Steroid injection
C. Oral NSAIDs
D. Foot orthoses

- **Long-term:** Both the Framingham study and a meta-regression analysis of randomized controlled trials by Christensen et al revealed a significant long-term reduction in pain and improvement in functional scores with weight loss.
- **Short-term:** Steroid injections are associated with short term, generally less than 12 weeks of pain relief. Oral NSAID usage should be limited to short term use because of increased risk of GI and cardiovascular system adverse effects with long-term use.
- Foot orthoses have weak evidence in the reduction of knee pain symptoms.

What percent weight reduction has been shown to help reduce disability related to symptomatic knee arthritis?

A. 1
B. 3
C. 7
D. 10

- Meta-regression analyses show that a 10% reduction in body weight is associated with a moderate or larger clinical improvement in disability.

A reasonable first line of treatment in osteoarthritis (OA) of the knee is:

A. Intra-articular injections
B. Oral steroids
C. Acetaminophen and/or nonsteroidal anti-inflammatory drugs (NSAIDs)
D. Colchicine

- The other choices are used in inflammatory arthritis, or as treatments for refractory OA, but not as a first-line treatment.

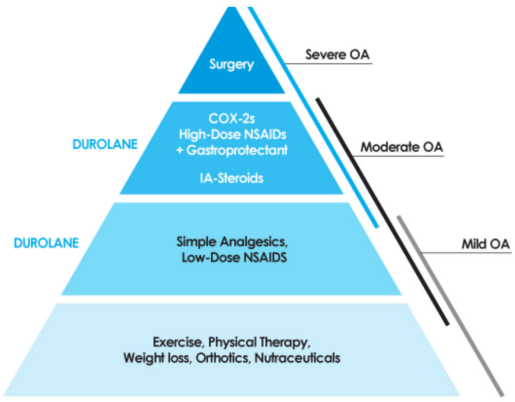

	↓Pain	↓Inflammation	MI/Stroke prevention
Ibuprofen	♤	♤	
Aspirin	♤	♤	♤

A 55-year-old male with a history of coronary artery disease, diabetes mellitus, and osteoarthritis is evaluated for right knee pain. He takes a low-dose aspirin daily for coronary protection. Concomitant use of which drug may negate the cardioprotective effects of aspirin?

A. Acetaminophen
B. Ibuprofen
C. Tramadol
D. Glucosamine

- In the clinical scenario where the patient with **OA** is taking low-dose aspirin (25mg per day) for cardioprotection and the practitioner chooses to use an oral NSAID, a multidisciplinary expert European panel strongly recommended using a non-selective NSAID other than ibuprofen in combination with a proton-pump inhibitor. This recommendation was based, in part, on the Food and Drug Administration's (FDA) warning that the concomitant use of ibuprofen and low-dose aspirin may render aspirin less effective when used for cardioprotection and stroke prevention because of a recognized pharmacodynamic interaction (possibly by competing with aspirin for a common docking site just below the critical acetylation site within the narrow hydrophobic channel of the COX-1 enzyme).
- Studies have not demonstrated this same type of pharmacodynamic interaction with diclofenac or celecoxib; nonetheless, the expert panel strongly recommended that a COX-2 selective inhibitor should not be used in the above situation. No specific recommendation was made regarding other individual NSAIDs. It should be noted, that aspirin may interfere with the GI-sparing effects of coxibs.
- Acetaminophen, tramadol, and glucosamine have not been shown to interfere with the cardioprotective effects of low-dose aspirin.

Isotonic contraction		**Isometric contraction**
Concentric contraction	**Eccentric contraction**	
muscle shortens (↓length)	muscle lengthens (↑length)	muscle contracts but dose not shorten (↑tension, ↔length)
upward phase of exercise	downward phase of exercise	holding the weight still
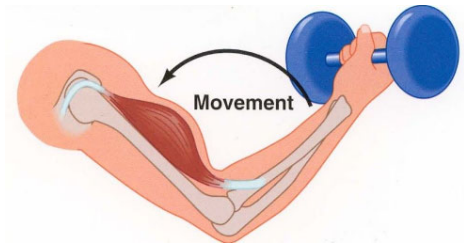	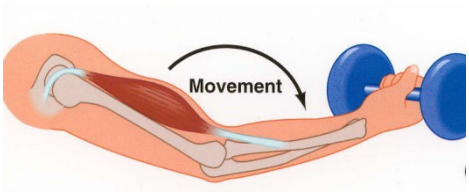	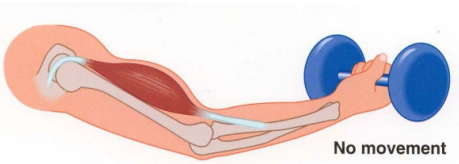

Match the Contractions to the correct definition.

Isometric contraction	■	□	**Muscle shortens**
Isotonic – Concentric contraction	■	□	**Muscle lengthens**
Isotonic – Eccentric contraction	■	□	**Tension builds but muscle neither shortens or lengthens**

Which of the following exercises is recommended for rheumatoid arthritis?

A. Isotonic contraction
B. Concentric contraction
C. Eccentric contraction
D. Isometric contraction

- Isometric contraction of a muscle does not cause a change in muscle length or joint angle and is ideal for **RA** because it allows the joint to rest.

Which of the following is NOT a part of rehabilitation of the hand in a patient with rheumatoid arthritis?

A. Heavy exercise of the involved joints
B. Resting the involved joints
C. Joint protection instructions
D. Splinting regimens

- In **RA**, it is important to rest the involved joints.
- Heavy exercise of the involved joints is contraindicated as it could cause more damage.
- Other important rehabilitation measures include modification of activities that stress the joints, joint protection, work simplification instructions, splinting regimens, heat modalities followed by active range of motion exercise, and resistive exercise.

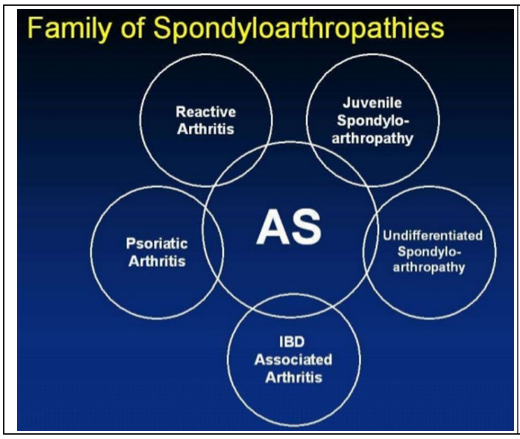

- Rheumatoid factor (RF) is usually negative in the spondyloarthropathies (hence, why they are called seronegative spondyloarthropathies).
- Seronegative spondyloarthropathies (seronegative spondyloarthritides) share certain clinical characteristics (eg, inflammatory back pain, uveitis, gastrointestinal symptoms, rashes).
- Some are strongly associated with the HLA-B27 (human leukocyte antigen B27) allele. Clinical and genetic similarities suggest that they also share similar causes or pathophysiologies.
- They include ankylosing spondylitis, reactive arthritis, psoriatic arthritis, and other disorders.

Which of the following is NOT associated with HLA-B27 (+) serology?

A. Reiter's syndrome (reactive arthritis)
B. Osteoarthritis
C. Psoriatic arthritis
D. Ankylosing spondylitis

- All of the choices above except osteoarthritis are associated with HLA-B27(+) serology.
- They are called seronegative arthropathies.
- Other HLA-B27(+) diseases include enteropathic arthropathy and pauciarticular juvenile rheumatoid arthritis.

Which of the following is NOT a seronegative arthritis?

A. Psoriatic arthritis
B. Reactive arthritis
C. Rheumatoid arthritis
D. Ankylosing spondylitis

- A seronegative arthritis is an arthritis in which the rheumatoid factor is negative.
- **Rheumatoid arthritis** is an autoimmune disease, usually with a positive rheumatoid factor, resulting in inflammation in tissue and joints.
- **Psoriatic arthritis** is often a milder inflammatory arthritis that develops in approximately 30% of patients who already suffer with psoriasis. During flares, the arthritic symptoms may worsen.
- **Reactive arthritis** is an autoimmune condition developed in response to a recent infection, particularly after a genital infection with Chlamydia trachomatis or after an episode of gastroenteritis by Campylobacter species. The triad of symptoms includes urethritis, conjunctivitis, and arthritis.
- **Ankylosing spondylitis** is a chronic inflammatory condition of the spine and sacroiliac joint with osseous formation.

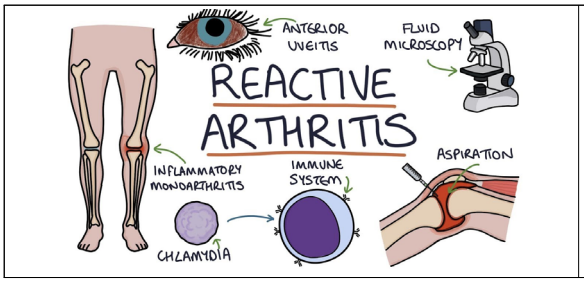

- Reactive arthritis is joint pain and swelling triggered by an infection in another part of the body — most often the intestines, genitals or urinary tract. Reactive arthritis usually targets the knees and the joints of the ankles and feet. Inflammation also can affect the eyes, skin and urethra.
- The infection usually occurs days to weeks before the onset of joint pain. In some cases a preceding infection may only be identified with laboratory testing.

• More likely among people with an HLA-B27 gene	• Triggered by a bacterial infection (sexually transmitted or foodborne illness)	• Often improves on its own within a few weeks or months

Which of the following is considered to be a HLA-B27 spondyloarthropathy?

A. Reactive arthritis
B. Polyarticular JRA
C. Pseudogout
D. Sarcoidosis

Reactive arthritis = **Reiter syndrome**

- The HLA-B27 spondyloarthropathies include psoriatic arthritis, ankylosing spondylitis, pauciarticular JRA, enteropathic arthropathy, and reactive arthritis (formerly known as Reiter syndrome)

Three weeks after visiting a petting zoo, a 40 year old female patient reports a spontaneous onset of knee pain and knee joint swelling. What is the most likely cause of her knee pain and swelling?

A. Meniscal tear
B. Osteoarthritis
C. Reactive arthritis
D. Baker cyst

- Reactive arthritis usually follows a gastrointestinal or urogenital infection. Common pathogens include Yersinia, Salmonella, Chlamydia trachomatis and Neisseria gonorrhea. Salmonella can typically be acquired at petting zoos.
- Reactive arthritis isn't contagious. However, the bacteria that cause it can be transmitted sexually or in contaminated food. Only a few of the people who are exposed to these bacteria develop reactive arthritis.
- The other options are less likely given the patient's age and lack of history that would support and anatomical injury.

Numerous bacteria can cause reactive arthritis. Some are transmitted sexually, and others are foodborne.					
Chlamydia	Salmonella	Shigella	Yersinia	Campylobacter	Clostridium difficile

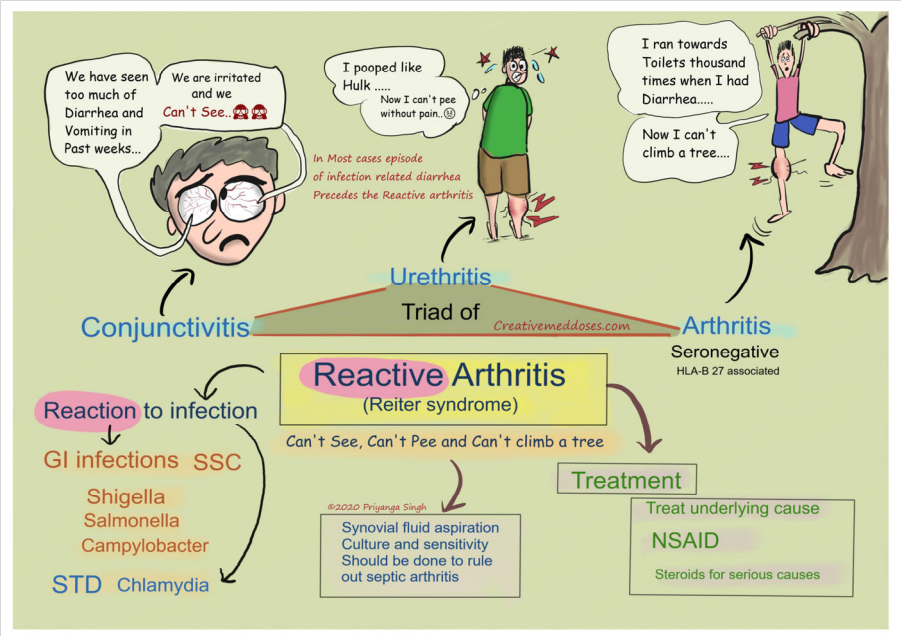

Reactive arthritis, or Reiter's syndrome, is made up of a triad of symptoms. Which of the following is NOT involved in Reactive arthritis?

A. Conjunctivitis
B. Urethritis
C. Arthritis
D. Pericarditis

- Reactive arthritis is an autoimmune condition developed in response to a recent infection, particularly after a genital infection with Chlamydia trachomatis or after an episode of gastroenteritis by Campylobacter species.
- The triad of symptoms includes conjunctivitis (CAN'T SEE), urethritis (CAN'T PEE), and arthritis (CAN'T CLIMB A TREE).
- The mechanism of action is unknown, but it is assumed to involve the migration of bacterial antigens into the affected triad sites which proceed to cause an inflammatory response.
- This syndrome is usually self-limiting, but if symptoms are more severe, a course of steroids and immunosuppressants may be indicated.

Conjunctivitis	Urethritis	Arthritis
"Can't see"	"Can't pee"	"Can't climb a tree"

- Ankylosing spondylitis is an inflammatory disease that, over time, can cause some of the small bones in your spine (vertebrae) to fuse.
- The condition is more common among men and usually begins in early adulthood.
- Symptoms typically appear in early adulthood and include reduced flexibility in the spine. This reduced flexibility eventually results in a hunched-forward posture. Pain in the back and joints is also common.
- Treatment includes medication, physical therapy, and in rare cases surgery.

Which joint/area of the body is affected first in ankylosing spondylitis (AS)?

A. Lumbar spine
B. Sacroiliac joint
C. Cervical spine
D. Thoracic spine

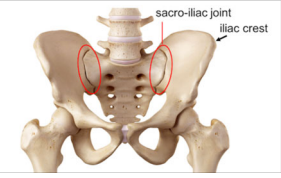

- In AS, the typical order of progression is that the sacroiliac joint is affected first, followed by the lumbar spine, thoracic spine, and lastly cervical spine.
- This is a distal to proximal progression.

Ankylosing spondylitis is associated with which of the following Human Leukocyte Antigen allele?

A. HLA-B47
B. HLA-B27
C. HLA-DR4
D. HLA-B72

- The human leukocyte antigen is synonymous with the major histocompatibility complex and describes a group of genes on chromosome 6.
- Ankylosing spondylitis is a chronic inflammatory disease of the axial skeleton commonly associated with HLA-B27.

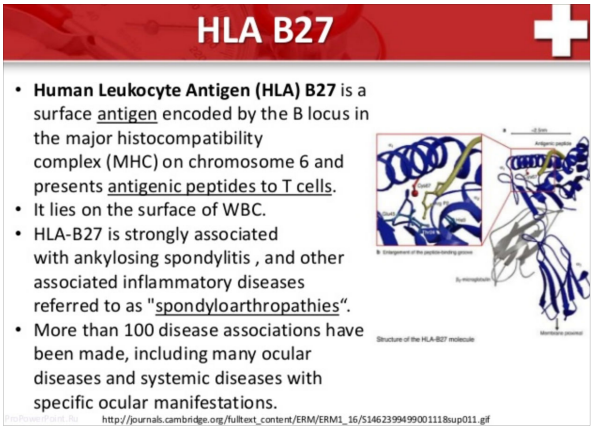

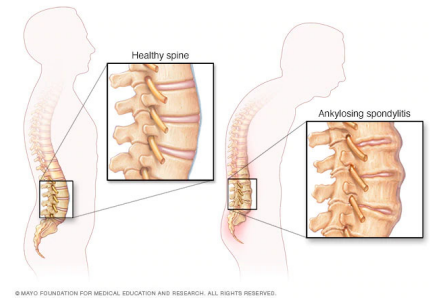

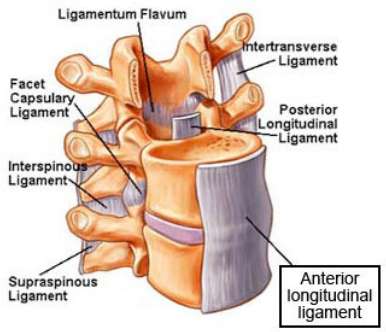

AS	DISH
Ossification of Anterior longitudinal ligament	
Reduced disk height	Preserved disk height
Presence of Sacroiliitis	Absence of Sacroiliitis
+ HLA-B27	- HLA-B27

Radiographic findings associated ankylosing spondylitis includes symmetric SI joint narrowing, osteopenia, and a "Bamboo spine." A "Bamboo spine" refers to ossification (bone formation) of which ligamentous structure?

A. Anterior longitudinal ligament
B. Posterior longitudinal ligament
C. Supraspinous ligament
D. Interspinous ligament

- This patient has ankylosing spondylitis. The hallmark is bilateral sacroiliitis.
- The formation of a bamboo spine on radiographic studies is secondary to ossification of the anterior longitudinal ligament and ankylosing of the apophyseal joint leading to complete fusion.

Which of the following sports would be contraindicated in a patient with ankylosing spondylitis?

A. Archery
B. Badminton
C. Bicycling
D. Table tennis

- Owing to the loss of joint and spinal motion in patients with ankylosing spondylitis, these patients should engage in range of motion exercises, including stretching and strengthening.
- Spinal extension exercises help decrease the severity of the condition.
- Ninety percent of patients with ankylosing spondylitis are HLA-B27 positive.

Sports that promote **spinal extension** are **favored**	Sports that require **spinal flexion** should be **avoided**
including archery, badminton, and table tennis.	including golf, bicycling, and bowling.

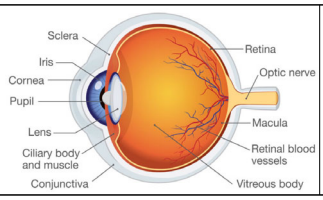

- **Conjunctivitis**, also known as pink eye, is inflammation of the outermost layer of the white part of the eye and the inner surface of the eyelid.
- **Uveitis** is a form of eye inflammation. It affects the middle layer of tissue in the eye wall (uvea).
- **Iritis** is the inflammation of the colored part of your eye (iris).
- **Iridocyclitis** is an inflammation of the iris (the colored part of the eye) and of the ciliary body (muscles and tissue involved in focusing the eye).

In a patient with ankylosing spondylitis, which specialist should you refer the patient to for further evaluation and treatment?

A. Infectious Disease
B. Gastroenterology
C. Optometrist
D. Ophthalmology

(i) Optician	(ii) Optometrist	(iii) Ophthalmologist
Dispenses corrective lenses to adjust a person's vision	Recognise and diagnose eye diseases and other chronic health problems	Medical doctors who specialise in the field of eye care, including performing surgery

- Ankylosing spondylitis is associated with conjunctivitis, uveitis, iritis, and iridocyclitis. All patients should be referred to an ophthalmologist for further evaluation and treatment.

Optometrist	Ophthalmologist
an eye doctor that can examine, diagnose, and treat the eyes.	a medical doctor who can perform medical and surgical interventions for eye conditions.

	LU	LI	ST	SP	HT	SI	UB	KD	PC	SJ	GB	LV
FIRE POINT	10	5	41	2	8	5	60	2	8	6	38	2
WATER POINT	5	2	44	9	3	2	66	10	3	2	43	8

YIN-YANG BALANCING ACUPUNCTURE (平針 평침)

		Ipsilateral		Contralateral	
		FIRE	WATER	FIRE	WATER
SYSTEM 1					
SYSTEM 2					
SYSTEM 3					
SYSTEM 4					
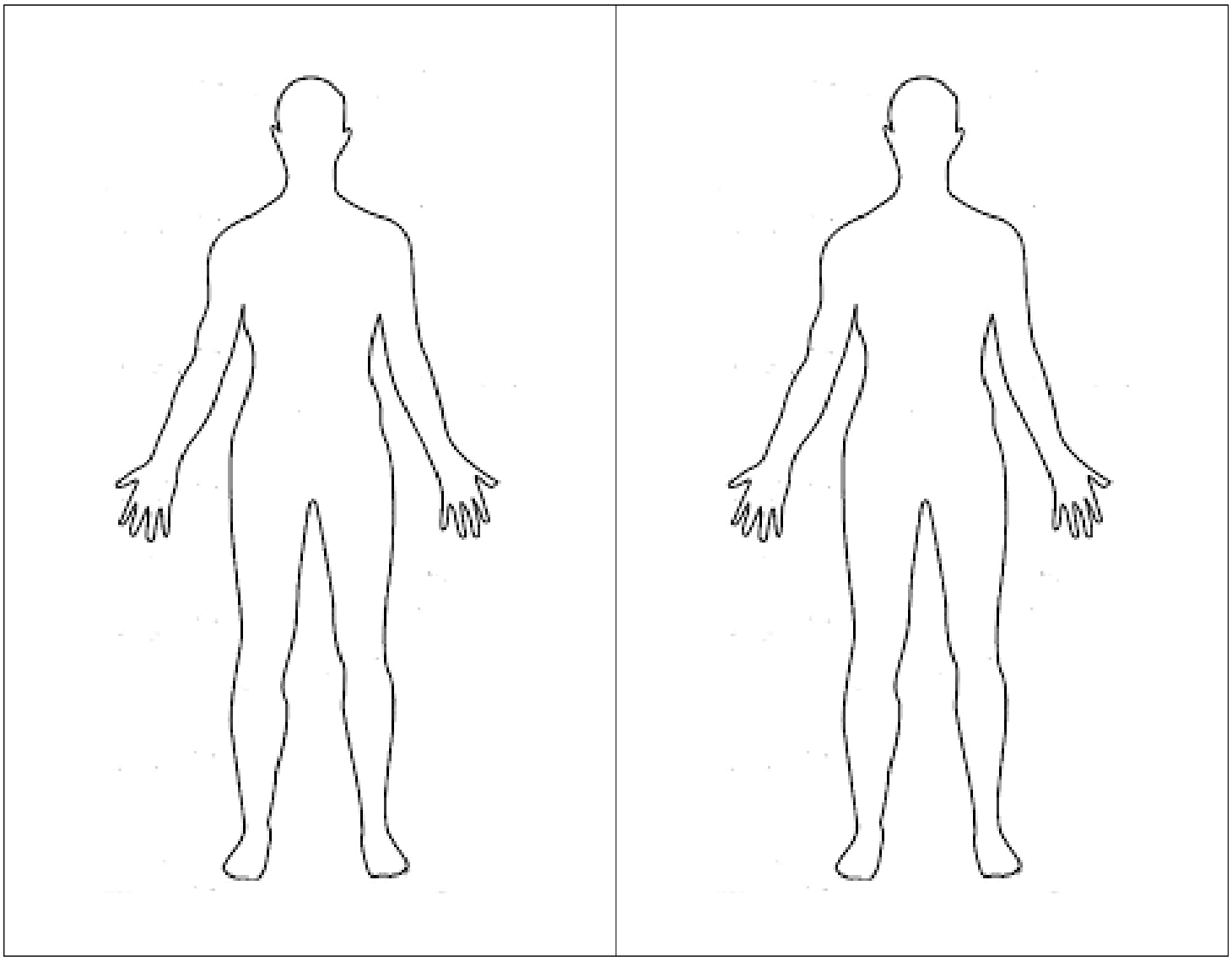
Minibook p.362